

See discussions, stats, and author profiles for this publication at: <https://www.researchgate.net/publication/336200084>

A case study: Effects of wet cupping therapy in a male with primary infertility

Article in *Journal of Complementary Medicine Research* · January 2019

DOI: 10.5455/jcmr.20190807074320

CITATIONS

7

READS

3,251

2 authors:



Senol Dane

Nile University of Nigeria

130 PUBLICATIONS 2,095 CITATIONS

[SEE PROFILE](#)



Menizibeya Osain Welcome

Nile University of Nigeria

192 PUBLICATIONS 431 CITATIONS

[SEE PROFILE](#)

Some of the authors of this publication are also working on these related projects:



Effects of red guava juice on hemoglobin and hematocrit levels in female adolescent students with anemia [View project](#)



Geriatric Physiology [View project](#)



A case study: Effects of wet cupping therapy in a male with primary infertility

Senol Dane, Menizibeya Osain Welcome

Department of Physiology, College of Health Sciences, Nile University of Nigeria, Abuja, Nigeria

ABSTRACT

Background and purpose: Infertility is a serious health problem, resulting from the inability of a sexually active couple to achieve pregnancy in 1 year. The cost of treatment remains a challenge for majority of infertile people. Alternative therapy may be helpful in addressing the problem of infertility. The purpose of this study was to investigate the effects of wet cupping therapy in a male with infertility.

Materials and methods: The patient was a 32-year-old male with a 7-year history of infertility. Pre- and post-tests were completed by testing the man's semen and human chorionic gonadotropin in his wife's serum. The man underwent wet cupping therapy twice each month. His wife was treated with wet cupping once per month.

Results: The wife of the man became pregnant after 2 months of wet cupping therapy.

Conclusion: Wet cupping therapy can be effective in treating individuals with infertility.

ARTICLE HISTORY

Received August 07, 2019

Accepted September 09, 2019

Published September 23, 2019

KEYWORDS

Wet cupping therapy;
alternative therapy;
infertility; male infertility;
pregnancy; conception

Introduction

Infertility is a serious, multifaceted public health problem, defined as the inability to achieve natural pregnancy after 12 months of regular, unprotected coitus. Infertility is estimated to affect 8%–15% or approximately 50 million of reproductive-aged couples worldwide [1–3]. However, in some regions of the world, the rate of infertility is much higher, reaching approximately 30% [1,4]. Such regions with high prevalence of infertility include South Asia, sub-Saharan Africa, Middle East, North Africa, Central Asia, Central and Eastern Europe [3]. According to Mascarenhas et al. [3], one in every four couples in developing countries is affected by infertility.

Infertility is categorized into two types: primary and secondary infertility. Primary infertility, according to the World Health Organization, can be defined as the inability of reproductive-aged woman (from 15 to 49 years old) to conceive after 1 year of sexually active life [5]. Secondary infertility is the inability to conceive after a previous pregnancy [6]. The incidence of the former is higher, compared to the latter [6]. A study conducted in South-Eastern Nigeria revealed that primary infertility accounted for 65% cases of infertility, whereas

secondary infertility was found in 35% [7]. About 20%–30% of infertility cases, contributing to 50% of cases overall, are due to male factors [8]. However, Ikechebelu et al. [7] reported 42% for male factors and only 26% for female factors in Nigeria, suggesting that male may have greater contribution to cases of infertility in some regions of the world. Similar findings are reported elsewhere [9,10]. These studies are contrasted with other reports, indicating that 50% of infertility cases are due to female factors [8]. This, probably, is a confirmation of reports suggesting that infertility research (including prevalence studies) is complicated due to male and female factors [3,11]. About 20%–30% of infertility cases are due to combined male and female factors [8]. Ikechebelu et al. [7] also reported a 21% combined male and female factors as possible causes of infertility in a sample of Nigerian infertile couples. About 11% cases are due to unexplained causes. Indeed, infertility is complicated and due to multiple causes, which include morphologic defects of sperm (teratozoospermia), reduced sperm count (oligozoospermia or oligospermia), motility disorder (asthenozoospermia), absence of spermatozoa in semen (azoospermia), poor

Contact Menizibeya Osain Welcome ✉ welcome.menizibeya@nileuniversity.edu.ng 📧 Department of Physiology, College of Health Sciences, Nile University of Nigeria

sperm quality, testicular maldescent, testicular torsion, vas deferens, or epididymis obstruction—responsible for more than 90% of cases of male infertility [7,10,12,13]. Genitourinary tract infection due to poorly treated sexual transmitted diseases and sexual promiscuity, critical illnesses, malnutrition, genetic abnormalities, gonadotoxic oncologic therapy, environmental pollutants, chronic stress, and lifestyle changes play an integral role in occurrence of infertility [2,7,12,13].

Infertility is associated with a range of consequences, which include societal burden and psychological disorders. For example, Direkvand-Moghadam et al. [14] reported that infertility is associated with marital discord and remarriage. In some cases, more than 50% of individuals with infertility experience some form of verbal or physical abuse [9].

Despite improvement in diagnostics and treatment, unaffordability, and inaccessibility of the procedures for majority of the infertile couples are major problems. In developing countries, in particular, the deplorable state of healthcare system and the high costs of the procedures have hindered many couples from having their babies [15]. Alternative therapy has been reported to improve sperm qualities [16,17], suggesting that this treatment option may be helpful in addressing the problem of infertility. Wet cupping therapy, which is a type of alternative therapy, is the most common type of cupping therapy [1]. The therapy involves creation of a vacuum over specific, mildly punctured zones on the skin, using vacuum pumping and disposable lancets [18]. Wet cupping therapy is currently gaining recognition all over the world due to its affordability and ability to alleviate symptoms of different ailments. For example, Arslan et al. [19] reported that cupping therapy reduces upper shoulder and neck pains in office workers. The benefits of this therapy have been reported for heart diseases [20,21] and other illnesses that affect humans [22,23]. Although previous studies suggest that wet cupping therapy improves sperm quality [24], the effect of wet cupping therapy on infertility is not fully known. The implication of changes of sperm quality following wet cupping therapy on the female's ability to conceive is not completely understood. Therefore, studies investigating the role of wet cupping in achieving pregnancy will not only add useful information to the literature but also certainly provide the basis for infertile couples who wish to utilize the therapy.

The purpose of this study was to investigate the effects of wet cupping therapy on infertility in a male with primary infertility.

Methods

Ethics

The study was carried out in accordance with the Helsinki Declaration (1975, revised 1996–2013) and approved by the local ethical and research committee (IRB/Nile/CHS/PHS 0011/2018). Written informed consent was obtained from the man and his wife after they had been thoroughly explained the methodology, purpose, benefits, and possible risks of the study.

Case

The case was a 32-year-old male waiter in a university canteen. He presented with complaints of inability to get his wife pregnant and premature ejaculation since the past 7 years despite having regular and unprotected sexual intercourse. The man also had upper and lower back pain and snoring complains. The wife of the man was 29-year old. According to the man, he was confirmed infertile in a hospital, where the physician advised him to do *in vitro* fertilization. However, he could not do it because he did not have the money to finance the procedure. He had normal secondary sexual characteristics. There was no history of systemic or chronic illness. He had no history of smoking and alcohol consumption.

Pre- and post-tests were completed by the researcher by investigating the semen fluid of the man and human chorionic gonadotropin (hCG) of his wife. Serum hCG analysis was negative for pregnancy. Laboratory exam of the semen revealed decreased sperm count, low motility, and abnormal sperm morphology (see result section for sperm quality indices upon presentation). Investigation of blood sugar, testosterone, and prolactin levels did not reveal any abnormalities. Abdominal ultrasonography was essentially normal with no varicose veins or hydrocele.

The man underwent wet cupping therapy twice per month on Wednesdays after every other week. Due to the possibility of combined male and female factors in infertility, his wife was also treated with wet cupping once per month during the second wet cupping therapy of her husband. The semen fluid of the man was investigated during and after wet

cupping therapy, while hCG of his wife's serum was analyzed after the therapy period.

Spermiogram

Semen collection was done according to the recommended standards [25,26]. Semen was collected before commencement of the study. Semen sample was also collected 15 days after the first cupping therapy and 15 days after completion of the study. In each case, semen was collected after 3–4 days of abstinence from sexual activity. Collection of semen was done by masturbation into sterile sample container and delivered to the laboratory within a period of 30 minutes after ejaculation. To prevent large changes in temperature, which may affect the spermatozoa, the specimen container was maintained at a temperature of 20°C–37°C.

The semen was analyzed by a certified andrologist. Analysis and interpretation of semen was carried out according to World Health Organization (2010) guidelines [27]. The functional indices of the semen were assessed according to earlier studies [28,29]. Concentration was determined by a Makler chamber (Sefi-Medical Instruments, Haifa) [30]. Sperm morphology was analyzed according to the Tygerberg Strict Criteria [31].

The man did not take any medications during the period of the study.

hCG testing

hCG is a hormone, which is produced early in pregnancy after implantation by trophoblast cells [32]. This hormone can be detected in the maternal blood as early as 8 days after implantation and peaks at around 100,000 mIU/ml at a gestational age of 10 weeks, and thereafter declines, maintaining a concentration of around 20,000 mIU/ml throughout the period of pregnancy [32]. Detection of this hormone is highly reliable and sensitive for determination of pregnancy [32].

The level of hCG was determined from blood samples drawn from the wife before commencement of the study and after 15 days after completion of the study. hCG analysis was carried out according to Korevaar et al. [33] and Strom et al. [34]. Serum hCG was analyzed by the chemiluminescent immunometric assay, calibrated against fourth World Health Organization International Standard 75/589, on an Immulite 2000 XPi system (Siemens Healthcare Diagnostics, Deerfield, IL).

The woman did not take any medications during the period of the study.

Wet cupping therapy

Wet cupping therapy was conducted by cupping practitioner (author SD), who is a certified physician of the British Cupping Society and National Health Institute. The cupping therapy was conducted according to previous recommendation [35] with modifications. The therapy was carried out on the posterior torso. The entire back was exposed and cleaned with antiseptics. Nine points of the posterior, bilateral thoracic, lumbar and sacral areas of the spine were selected for treatment (Fig. 1). These spinal areas are implicated in regulating autonomic functions of the reproductive organs [36,37]. Sterile disposable cups measuring about 5 cm in diameter were consecutively placed at the points, mentioned above, and negative pressure was applied by cupping (vacuum) pump. After about 2–3 minutes of pumping in each point, the cups were removed. The point of the skin to which cupping pressure was applied was first punctured with 26-gage disposable lancets to a 2 mm depth. Thereafter, vacuum pumping was applied for the second time, draining about 3–5 cm³ of blood per cupping site. The application sites were cleaned with sterile pads. As a measure against negative reactions to bloodletting or pain intolerance, an emergency physician and a nurse with emergency response kit were ready in the application room to promptly respond to negative consequences that would occur during the cupping procedure. Negative reaction did not occur during the procedure.

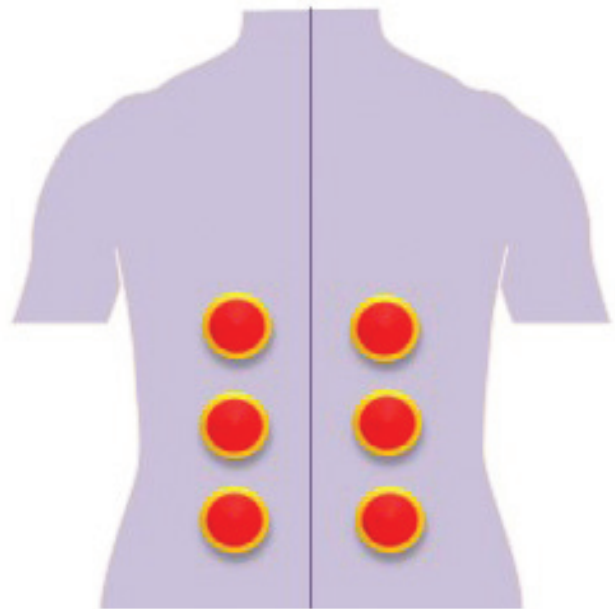


Figure 1. Posterior torso showing points on the skin where wet cupping therapy was applied.

Results

Table 1 displays the results of spermiogram indices before and after wet cupping therapy.

Before therapy, there was low volume of ejaculation, which increased up to 4 ml after therapy. The man had oligozoospermia before therapy. During therapy period, sperm count increased, and further above the threshold for normal referred to as normospermia (Table 1). Similarly, proportion of spermatozoa with normal morphology was observed to have increased during wet cupping therapy. Upon completion of the therapy, spermiogram had normal morphology (i.e., 60% of the sperms had spermatozoa normal morphology), required for successful fertilization. Before therapy, motility was lower than normal, but increased during and after completion of therapy. Sperm vitality also increased after the period of therapy (Table 1). The semen pH did not substantially change before, during, and after completion of the therapy (range 7.1–7.7 units) (Table not shown).

Upon completion of therapy, semen sample became normozoospermic. Premature ejaculation, back pain, and snoring were present before the therapy, but disappeared after the therapy.

The wife of the man became pregnant after wet cupping therapy. The level of hCG was negative before cupping therapy, but became positive (at 49.57 mIU/ml) after therapy, indicating the presence of pregnancy.

Discussion

Infertility is a growing health problem worldwide with considerable social, medical, and financial effects [38]. Several studies have reported that couples suffer several societal issues due to infertility [9,14,38]. Furthermore, infertility negatively affects the quality of life of couples [39]. Though there are a range of infertility treatment options

such as surgical (e.g., in obstructive azoospermia), medical (administration of androgens, gonadotropins, anti-estrogens, antibiotics, antioxidants, etc.), and assisted reproductive therapy (*in vitro* fertilization and intra cytoplasmic sperm injection) [40], no approach guarantees absolute effectiveness. For example, though *in vitro* fertilization and intra cytoplasmic sperm injection are the preferred approaches for addressing the problems of infertility, there is always a chance of fertilization failure, which is due to a range of factors, including sperm defects [40–42]. More importantly, the cost of assisted reproductive therapy remains a huge challenge for the majority of people, especially in developing countries [9,14]. More so, structural abnormalities of the fetus resulting from the procedure cannot be excluded [43,44].

Recent investigations have suggested that alternative therapy can alleviate the suffering of infertile couples [16,17]. For example, a recent study showed that acupuncture increases the chances of pregnancy from 26% to 43% [45]. As a type of alternative therapy, wet cupping may have positive effect on infertility, similar to that exerted by acupuncture therapy. Indeed, the results of our study indicate that wet cupping therapy can be effective in infertility treatment. Thus, wet cupping is a promising therapeutic option in alternative medicine that can potentially revert the repercussions of infertility.

The spermiogram results in this study showed improvement during the therapy and subsequently became normal after 2 months of wet cupping therapy. Also, the man's premature ejaculation also completely disappeared after therapy. Semen analysis provides essential information on male's fertility potential, and also, essential in evaluating success of treatment of infertility [38]. Indices of spermiogram, such as volume, sperm count, motility, morphology, and vitality, are crucial indicators of fertility outcome *in vivo*. These indices provide data

Table 1. Spermiogram results and ejaculation status before and after wet cupping therapy.

	Before therapy	15 days after the first therapy	15 days after the second therapy
Volume (ml)	1.5	2	4
Sperm count (million/ml)	11	19	43
Morphology (%normal)	27	43	71
Motility (%normal)	31	44	65
Vitality (%)	29	47	66
Premature ejaculation	Mild	Normal	Normal

on semen quality and fertility potential, thereby affecting the chances of conception [38,46]. For instance, adequate spermatozoa motility is required for effective penetration of the cervical mucus, transport through the female genital tract, and penetration through the corona radiata and zona pellucida before fertilization can take place [38]. For fertilization to take place, 50% of spermatozoa must have a progression rate of at least 25 $\mu\text{m/s}$, but not less than 5 $\mu\text{m/s}$ at about 20°C–37°C [46]. It is recommended that sperms be checked for viability if at least 50% sperms are immotile [27,46]. Motility and viability are very important spermogram indices for deciding on the type of treatment options for couple's infertility [27]. Thus, disordered spermatozoa motility or less than 32% motile sperms (asthenozoospermia), low sperm count (oligospermia), and abnormal morphology (teratozoospermia) can lead to infertility. A combination of the aforementioned disorders of spermogram indices substantially decreases the fertility potential of males. The man in this study before wet cupping therapy had disorders in almost all spermogram indices (i.e., oligoastheno-teratozoospermia). However, during therapy, these indices improved, and after therapy, his spermogram showed a normal result (i.e., normozoospermia). Like the motility disorder, the vitality of the patient's sperm was also below 58% upon presentation, but exceeded the normal value, thus increasing fertility potential of the man.

Premature ejaculation, defined as short ejaculatory time or latency between vaginal intromission and intravaginal ejaculation due to loss of control with associated psychological distress in the partner [47], is one of the most frequent sexual disorders, experienced by infertile males. The lack of efficient treatment, in addition to poorly defined criteria for this sexual dysfunction has made premature ejaculation a critical problem that substantially interferes with infertility treatment success [48–50]. Ejaculatory latency of 20–1,200 seconds can occur in premature ejaculation, but ejaculatory latency in some healthy males may overlap with latency of infertile patients [51]. Though there is lack of widely accepted criteria, assessment of premature ejaculation basically relies on self-report, which may not be reliable at all times. Normal ejaculatory latency is believed to be around 3–6 minutes [51]. The man in this study reported impaired ejaculatory time; however, after wet cupping therapy, his ejaculation became normal as evidenced by normal spermogram results, which resulted to wife's pregnancy. Pregnancy was

confirmed by hCG analysis. But hCG test prior to wet cupping therapy showed negative result. Analysis of this hormone is recommended and used worldwide to test for pregnancy. Research data have shown that hCG test is very reliable and highly sensitive for detection of pregnancy [32].

Though female factors such as tubal occlusion and high acidity of the genital tract milieu are crucial in infertility [7], increasing reports in Nigeria and other parts of the world have shown that male factors may even play a greater role in couple's infertility [7,52–54]. For example, Ikechebelu et al. [7] reported greater contribution of male factors to infertility. This indicates the necessity of paying considerable attention to men when couples present with infertility problem in Nigeria.

The mechanisms of effects of wet cupping therapy on infertility are not exactly known, but emerging data suggest that this therapy may regulate the level of reproductive hormones. In a recent study, Abduljabbar et al. [55] reported significant changes in hormonal profile in infertile women after wet cupping therapy. Thus, the effects resulting from the application of this therapy involve stimulation of some hormones [18]. The effect of wet cupping therapy may also be associated with removal of waste from the body. Moreover, local damage of the skin and capillary vessels due to this therapy acts as a nociceptive stimulus that triggers specific regions of the nervous system [18]. Wet cupping therapy has been reported to stimulate both the peripheral [56] and autonomic nervous system functions [18].

Therefore, wet cupping therapy can amplify sexual potency of an infertile man, correct defective semen, disturbed sexual functions, and improve spermatogenesis in male, and achieve conception of healthy progeny in a female.

Conflict of Interest

The authors report that there is no conflict of interest regarding the publication of this paper.

References

- [1] Ombelet W, Cooke I, Dyer S, Serour G, Devroey P. Infertility and the provision of infertility medical services in developing countries. *Hum Reprod Update* 2008; 14:605–21.
- [2] Petraglia F, Serour GI, Chapron C. The changing prevalence of infertility. *Int J Gynaecol Obstet* 2013; 123:S4–8.
- [3] Mascarenhas MN, Flaxman SR, Boerma T, Vanderpoel S, Stevens GA. National, regional, and global trends in infertility prevalence since 1990:

- a systematic analysis of 277 health surveys. *PLoS Med* 2012; 9:e1001356.
- [4] Nachtigall RD. International disparities in access to infertility services. *Fertil Steril* 2006; 85:871–5.
 - [5] World Health Organization. Reproductive health indicators for global monitoring: Report of the second interagency meeting. World Health Organization, Geneva, Switzerland, 2001.
 - [6] Inhorn MC. Global infertility and the globalization of new reproductive technologies: illustrations from Egypt. *Soc Sci Med* 2003; 56:1837–51.
 - [7] Ikechebelu JI, Adinma JI, Orié EF, Ikegwuonu SO. High prevalence of male infertility in southeastern Nigeria. *J Obstet Gynaecol* 2003; 23:657–9.
 - [8] Agarwal A, Mulgund A, Hamada A, Chyatte MR. A unique view on male infertility around the globe. *Reprod Biol Endocrinol* 2015; 13:37.
 - [9] Omoaregba JO, James BO, Lawani AO, Morakinyo O, Olotu OS. Psychosocial characteristics of female infertility in a tertiary health institution in Nigeria. *Ann Afr Med* 2011; 10:19–24.
 - [10] Ahmed A, Bello A, Mbibu NH, Maitama HY, Kalayi GD. Epidemiological and aetiological factors of male infertility in northern Nigeria. *Niger J Clin Pract* 2010; 13:205–9.
 - [11] Eric SN, Cyriac DD, Justine B, Jean L, Noël PJ. Who is responsible for couple infertility: a clinic-based survey in Ouagadougou (Burkina Faso). *Int J Nurs Midwif* 2017; 9:10–6.
 - [12] Sharlip ID, Jarow JP, Belkar AM, Lipshultz LI, Sigman M, Thomas AJ, et al. Best practice policies for male infertility. *Fertil Steril* 2002; 77:873–82.
 - [13] Esimai OA, Orji EO, Lasisi AR. Male contribution to infertility in Ile-Ife, Nigeria. *Niger J Med* 2002; 11:70–2.
 - [14] Direkvand-Moghadam A, Sayehmiri K, Delpisheh A, Direkvand-Moghadam A. The global trend of infertility: an original review and meta-analysis. *Int J Epidemiol Res* 2014; 1:35–43.
 - [15] Inhorn MC, Patrizio P. Infertility around the globe: new thinking on gender, reproductive technologies and global movements in the 21st century. *Hum Reprod Update* 2015; 21:411–26.
 - [16] Kim K II, Jo J. The effectiveness of Korean medicine treatment in male patients with infertility: a study protocol for a prospective observational pilot study. *Medicine (Baltimore)* 2018; 97:e9696.
 - [17] Bardaweel SK. Alternative and antioxidant therapies used by a sample of infertile males in Jordan: a cross-sectional survey. *BMC Complement Altern Med* 2014; 14:244.
 - [18] Yoo SS, Tausk F. Cupping: East meets West. *Int J Dermatol* 2004; 43:664–5.
 - [19] Arslan M, Yaman G, Ilhan E, Alemdag M, Bahar A, Dane S. Moving dry cupping therapy reduces upper shoulder and neck pain in office workers. *Clin Invest Med* 2015; 38:E217–20.
 - [20] Shekarforoush S, Foadoddini M, Noroozadeh A, Akbarinia H, Khoshbaten A. Cardiac effects of cupping: myocardial infarction, arrhythmias, heart rate and mean arterial blood pressure in the rat heart. *Chin J Physiol* 2012; 55:253–8.
 - [21] Arslan M, Yesilcam N, Aydin D, Yuksel R, Dane S. Wet cupping therapy restores sympathovagal imbalances in cardiac rhythm. *J Altern Complement Med* 2014; 20:318–21.
 - [22] Arslan M, Kutlu N, Tepe M, Yilmaz NS, Ozdemir L, Dane S. Dry cupping therapy decreases cellulite in women: a pilot study. *Indian J Tradit Knowle* 2015; 14:359–64.
 - [23] Cikar S, Ustundag G, Haciabdullahoglu S, Yuksel S, Dane S. Wet cupping(hijamah) increases sleep quality. *Clin Invest Med* 2015; 38:E258–61.
 - [24] Nimrouzi M, Mahbodi A, Jaladat AM, Sadeghfard A, Zarshenas MM. Hijamat in traditional Persian medicine: risks and benefits. *J Evid Based Complement Altern Med* 2014; 19:128–36.
 - [25] La Vignera S, Calogero AE, Condorelli R, Garrone F, Vicari E. Spermogram: techniques, interpretation, and prognostic value of results. *Minerva Endocrinol* 2007; 32:115–26.
 - [26] Mayorga-Torres JM, Agarwal A, Roychoudhury S, Cadavid A, Cardona-Maya WD. Can a short term of repeated ejaculations affect seminal parameters? *J Reprod Infertil* 2016; 17:177–83.
 - [27] World Health Organization. WHO laboratory manual for the examination and processing of human semen. WHO Press, Geneva, Switzerland, 2010.
 - [28] Cardona Maya WD, Berdugo Gutierrez JA, de los Rios J, Cadavid Jaramillo AP. Functional evaluation of sperm in Colombian fertile men. *Arch Esp Urol* 2007; 60:827–31.
 - [29] Mayorga-Torres BJ, Cardona-Maya W, Cadavid A, Camargo M. Evaluation of sperm functional parameters in normozoospermic infertile individuals. *Actas Urol Esp* 2013; 37:221–7.
 - [30] Cardona-Maya W, Berdugo J, Cadavid A. Comparing the sperm concentration determined by the Makler and the Neubauer chambers. *Actas Urol Esp* 2008; 32:443–5.
 - [31] Kruger TF, Menkveld R, Stander FS, Lombard CJ, Van der Merwe JP, van Zyl JA, et al. Sperm morphologic features as a prognostic factor in in vitro fertilization. *Fertil Steril* 1986; 46:1118–23.
 - [32] Gnoth C, Johnson S. Strips of hope: accuracy of home pregnancy tests and new developments. *Geburtshilfe Frauenheilkd* 2014; 74:661–9.
 - [33] Korevaar TIM, Steegers EAP, de Rijke YB, Schalekamp-Timmermans S, Visser WE, Hofman A, et al., Reference ranges and determinants of total hCG levels during pregnancy: the Generation R Study. *Eur J Epidemiol* 2015; 30:1057–66.
 - [34] Strom CM, Bonilla-Guererro R, Zhang K, Doody KJ, Tourgeman D, Alvero R, et al. The sensitivity and

- specificity of hyperglycosylated hCG (hhCG) levels to reliably diagnose clinical IVF pregnancies at 6 days following embryo transfer. *J Assist Reprod Genet* 2012; 29:609–14.
- [35] Umar NK, Tursunbadalov S, Surgun S, Welcome MO, Dane S. The effects of wet cupping therapy on the blood levels of some heavy metals: a pilot study. *J Acupunct Meridian Stud* 2018. pii: S2005-2901(18)30074-8. doi: 10.1016/j.jams.2018.06.005.
- [36] Mahmoud HS, Abou-El-Naga M, Omar NAA, El-Ghazzawy HA, Fathy YM, Nabo MM, et al. Anatomical sites for practicing wet cupping therapy (Al-Hijamah): in light of modern medicine and prophetic medicine. *Altern Integ Med* 2013; 2:138; doi:10.4172/2327-5162.1000138
- [37] Qureshi NA, Alkhamees OA, Alsanad SM. Cupping therapy (Al-Hijamah) points: a powerful standardization tool for cupping procedures? *J Complement Altern Med Res* 2017; 4(3):1–13. Article no.JO-CAMR.39269; doi:10.9734/JOCAMR/2017/39269
- [38] Rashad MM, Mostafa EM, El Shereen SF, Halim HM. Interpretation of spermograms among infertile Egyptian males in the Suez Canal region. *Hum Androl* 2013; 3:21–8.
- [39] Santoro N, Eisenberg E, Trussell JC, Craig LB, Gracia C, Huang H, et al., Fertility-related quality of life from two RCT cohorts with infertility: unexplained infertility and polycystic ovary syndrome. *Hum Reprod* 2016; 31:2268–79.
- [40] National Collaborating Centre for Women's and Children's Health. NICE Clinical Guidelines, No. 156, Fertility—assessment and treatment for people with fertility problems. Royal College of Obstetricians & Gynaecologists, London, UK, 2013.
- [41] Kahyaoglu I, Demir B, Turkkanı A, Cınar O, Dilbaz S, Dilbaz B, Mollamahmutoglu L. Total fertilization failure: is it the end of the story? *J Assist Reprod Genet* 2014; 31:1155–60.
- [42] Barlow P, Englert Y, Puissant F, Lejeune B, Delvigne A, Van Rysselberge M, et al. Fertilization failure in IVF: why and what next? *Hum Reprod* 1990; 5:451–6.
- [43] Tandulwadkar S, Lodha P, Khar V. Congenital malformations and assisted reproductive technique: where is assisted reproductive technique taking us? *J Hum Reprod Sci* 2012; 5:244–7.
- [44] Fedder J, Loft A, Parner ET, Rasmussen S, Pinborg A. Neonatal outcome and congenital malformations in children born after ICSI with testicular or epididymal sperm: a controlled national cohort study. *Hum Reprod* 2013; 28:230–40.
- [45] Zheng CH, Huang GY, Zhang MM, Wang W. Effects of acupuncture on pregnancy rates in women undergoing in vitro fertilization: a systematic review and meta-analysis. *Fertil Steril* 2012; 97:599–611.
- [46] Vasan SS. Semen analysis and sperm function tests: How much to test? *Indian J Urol* 2011; 27:41–8.
- [47] Lue TF, Giuliano F, Montorsi F. Summary of the recommendations on sexual dysfunctions in men. *J Sex Med* 2004; 1:6–23.
- [48] Abdel-Hamid IA, Jannini EA, Andersson KE. Premature ejaculation: focus on therapeutic targets. *Expert Opin Ther Targets* 2009; 13:175–93.
- [49] Barnes T, Eardley I. Premature ejaculation: the scope of the problem. *J Sex Marital Ther* 2007; 33:151–70.
- [50] Richardson D, Green J, Ritcheson A, Goldmeier D, Harris JR. A review of controlled trials in the pharmacological treatment of premature ejaculation. *Int J STD AIDS* 2005; 16:651–8.
- [51] Tarhan F, Tarhan H, Karaogullarından U, Can E, Divrik T, Zorlu F. Premature ejaculation in patients with ankylosing spondylitis. *Int J Androl* 2012; 35:74–8.
- [52] Benksim A, Elkhoudri N, Addi RA, Baali A, Cherkaoui M. Difference between primary and secondary infertility in Morocco: frequencies and associated factors. *Int J Fertil Steril* 2018; 12:142–6.
- [53] Akinloye O, Truter EJ. A review of management of infertility in Nigeria: framing the ethics of a national health policy. *Int J Womens Health* 2011; 3:265–75.
- [54] Hollos M, Larsen U, Obono O, Whitehouse B. The problem of infertility in high fertility populations: Meanings, consequences and coping mechanisms in two Nigerian communities. *Soc Sci Med* 2009; 68:2061–8.
- [55] Abduljabbar H, Gazzaz A, Mourad S, Oraif A. Hijama (wet cupping) for female infertility treatment: a pilot study. *Int J Reprod Contracept Obstet Gynecol* 2016; 5:3799–801.
- [56] Lee MS, Kim JI, Ernst E. Is cupping an effective treatment? An overview of systematic reviews. *J Acupunct Meridian Stud* 2011; 4(1):1–4.